

# Feasibility of Using Mobile Smartphone Camera as an Imaging Device for Screening of Cervical Cancer in a Low-resource Setting

<sup>1</sup>Rashmi Bagga, <sup>2</sup>Vanita Suri, <sup>3</sup>Radhika Srinivasan, <sup>4</sup>Niranjan Khandelwal, <sup>5</sup>Payal Keswarpu, <sup>6</sup>Sarif Kumar Naik  
<sup>7</sup>Vidya Chandrasekhar, <sup>8</sup>Lovi Gupta, <sup>9</sup>Soubhik Paul

## ABSTRACT

**Objective:** The aim of this study is to determine the feasibility of a screening method for cervical cancer using an application developed on smartphone to aid visual inspection with acetic acid.

**Materials and methods:** A prospective study was carried out in 230 women in the Department of Gynaecology, PGIMER, Chandigarh, India. These women were divided into two groups. Among the first group, screen positive women (n=28) were examined by two gynecologists. In the second group (n=202), health care workers screened women in a mobile van. The two groups were examined using the smartphone and digital colposcope. Abnormal findings were confirmed by liquid-based cytology and histopathology. The image quality of ColpPhon<sup>®</sup> was compared with colposcopic images as the gold standard. Kappa was used for comparison of ColpPhon<sup>®</sup> and colposcopic findings for final diagnosis.

**Results:** Among the 230 women screened, cervical intraepithelial neoplasia (CIN) was diagnosed in six cases by histopathology (CIN 2/3 in five and CIN 1 in one). These six women belonged to the group of 28 women examined in the colposcopy clinic. Both colposcope and ColpPhon<sup>®</sup> were able to identify these six women. The individual image quality parameters for ColpPhon<sup>®</sup> were slightly inferior to the colposcope. The overall image clarity had an agreement in 82% (184/225) as being either good or excellent. The diagnosis made on images acquired from each device had an agreement in 90% (208/230) of the cases.

**Conclusion:** This study demonstrates feasibility of incorporating a smartphone device to capture images of the cervix for improving cervical cancer screening in resource-poor countries.

**Keywords:** Cervical cancer, Early detection, Low-resource setting, Mobile device, Smartphone.

**How to cite this article:** Bagga R, Suri V, Srinivasan R, Khandelwal N, Keswarpu P, Naik SK, Chandrasekhar V, Gupta L, Paul S. Feasibility of Using Mobile Smartphone Camera as an Imaging Device for Screening of Cervical Cancer in a Low-resource Setting. J Postgrad Med Edu Res 2016;50(2):69-74.

**Source of support:** The study was supported by Philips India Ltd.

**Conflict of interest:** None

## INTRODUCTION

Cervical cancer is the most common cancer in Indian women, accounting for nearly 22.9% of new cancer cases and 20.7% of all cancer-related deaths in the country.<sup>1</sup> Mortality due to cervical cancer is more than 88% in low-income countries, and this by 2030 is predicted to rise to 91.5%.<sup>2</sup> In hospital-based cancer registries (HBCRs), cervical cancer was the leading cause of cancer in Bengaluru and Chennai, the second in Mumbai and Thiruvananthapuram, and the third in Dibrugarh.<sup>3</sup> Most cervical cancer cases are detected in late stage in developing countries primarily due to lack of regular screening programs. According to World Health Organization (WHO), the risk of cervical cancer reduces by 25 to 30% even if screening is done once-in-a lifetime on women in their thirties or forties.<sup>4</sup>

There are several screening tests in practice to identify pre-cancerous lesions. Cytology-based Pap-test, visual inspection with acetic acid (VIA), with or without Lugol's iodine (VILI), and the human papilloma virus (HPV)-DNA test are the prominent methods being practiced across the world. In the high-income countries, Pap-test and HPV-DNA based screening programs are highly effective. However, health systems in developing countries are not well-equipped to effectively promote Pap-test based screening for all women.<sup>2</sup> Therefore, VIA has been advocated as a screening technique. A meta-analysis to assess various screening tests in over 58,000 women in India and Africa found VIA and VILI to be

<sup>1-4</sup>Professor, <sup>5,9</sup>Scientist, <sup>6</sup>Principal Scientist, <sup>7</sup>Structure Engineer, <sup>8</sup>Clinical Research Analyst

<sup>1,2</sup>Department of Obstetrics and Gynaecology, Postgraduate Institute of Medical Education and Research, Chandigarh India

<sup>3</sup>Department of Cytology and Gynae-Pathology, Postgraduate Institute of Medical Education and Research, Chandigarh India

<sup>4</sup>Department of Radiodiagnosis, Postgraduate Institute of Medical Education and Research, Chandigarh, India

<sup>5</sup>Philips Health Systems, Hawthorne, New York, North America

<sup>6-9</sup>Philips Research India, Philips Innovation Campus, Bengaluru Karnataka, India

**Corresponding Author:** Rashmi Bagga, Professor, Department of Obstetrics and Gynaecology, Postgraduate Institute of Medical Education and Research, Chandigarh, India, Phone: 09872494602, e-mail: rashmibagga@gmail.com

reasonably accurate. Each woman underwent VIA and one or more other screening tests; the reference standard was colposcopy with histopathology or a negative colposcopy.<sup>5</sup> The visual inspection with acetic acid showed a sensitivity of 79% [95% confidence interval (95% CI) 73–85] and a specificity of 85% (95% CI 81–89) for cervical intraepithelial neoplasia (CIN)2+. Visual inspection with acetic acid with or without Lugol's iodine was 10% more sensitive and equally specific. Visual inspection with acetic acid with magnification (VIAM) showed similar results as VIA. The Pap smear showed lowest sensitivity for CIN2+ (57%; 95% CI 38–76) but had a higher specificity (93%; 95% CI 89–97). The HPV-DNA by hybrid capture 2 (HC2-assay) showed a sensitivity for CIN2+ of 62% (95% CI 56–68) and a specificity of 94% (95% CI 92–95). The results of visual tests and colposcopy showed a very high correlation. The limitation of this meta-analysis was that because of this correlation and possible overdiagnosis of CIN2+ by pathologists, the sensitivity and specificity of VIA and VILI were overestimated.<sup>5</sup>

The result of VIA screening is dependent upon the skill of the health care worker. During a VIA, digital images can be easily captured and saved for subsequent review by colposcopists for a quality check. Currently, mobile phones are commonly available, inexpensive, and have good quality cameras. Using a smartphone device, with an application to capture images during VIA, may be a low-cost scalable screening technique. It is expected to be more objective (with reproducible results) than VIA performed and interpreted only by a health care worker.<sup>6</sup> One such application is developed on an Android-based smartphone and the present study was carried out to see its feasibility for screening women for cervical cancer.

## MATERIALS AND METHODS

This prospective study was carried out in two groups of women from March to September 2014. The study was approved by the Institutional Ethics Committee of Postgraduate Institute of Medical Education and Research (PGIMER), Chandigarh. Group 1 women (n=28) were scheduled for colposcopy in the colposcopy clinic of the Department of Obstetrics and Gynaecology of the PGIMER, Chandigarh, India. Group 2 women (n=202) were attending an outreach screening program in which a mobile van (Asha Jyoti) screens women for cervical cancer, breast cancer, and osteoporosis. Asha Jyoti is a population-based screening program of women in the age group of 30 to 65 years, which aims to ensure early detection of breast cancer, cervical cancer, and osteoporosis. This was initiated jointly by Philips Health care, PGIMER (Chandigarh), and RAD-AID (USA).

The study was designed as open-label, as it was conducted to test the technical feasibility of implementation of the mobile phone based imaging device for screening for cervical cancer in existing health care infrastructure. Women between 30 and 65 years who voluntarily consented to participate were enrolled. Women who had undergone a hysterectomy were excluded. A written consent was obtained from all women. This consent also included consent for publication of study outcome while protecting the identity of women who participated. The confidentiality was maintained by keeping the phone under lock and key by the investigators when not in use. It was used only by the investigators and the two staff nurses of the Asha Jyoti mobile van. Once recorded, the data were encrypted and could be accessed only by the authorized persons. Colposcopy was performed in the colposcopy clinic by two gynecologists trained and practicing for >10 years in colposcopy using a digital video colposcope (Borze, India, Ltd, Delhi-NCR, India). In the Asha Jyoti van, cervical cancer screening is carried out by health care workers using a similar colposcope to obtain digital images after acetic acid and Lugol's iodine application, which are reviewed by a gynecologist in PGIMER. The women enrolled in the present study underwent colposcopy (in the colposcopy clinic) or routine screening (in the Asha Jyoti van), and during the same examination, images were also obtained by the hand-held mobile phone device (ColpPhon™). ColpPhon™ is an Android-based mobile application that uses the camera and light-emitting diode (LED) flashlight of any mobile with 8MP camera. The application has functionality to register patients, add clinical history, capture images, and send the case history for second review / tele consultation. The app has special features, such as workflow assistance and reminder for timer before acetic acid phase. All images were reviewed independently by two gynecologists and the images obtained by the colposcope were compared with those obtained by the ColpPhon™. The clinical factors analyzed were visibility of the transformation zone (TZ), acetowhite appearance (ACW), Lugol's iodine uptake, and overall diagnosis. The image quality parameters were brightness, glare, sharpness, and clarity. These were accorded a scale of 1 to 5, with 1 being very poor; 2: poor, 3: average, 4: good, and 5: being excellent.

## RESULTS

Among the 230 women screened, CIN was diagnosed on histopathology in six women (CIN 2/3 in five and CIN 1 in one). These six women belonged to the group of 28 women examined in the colposcopy clinic. All six had been identified as abnormal by the colposcope and ColpPhon™ both. Table 1 summarizes the indications

**Table 1:** Indications for colposcopy and distribution of women who underwent colposcopy by a gynecologist in hospital or by a nurse in an outreach setting in the Asha Jyoti van

	Number of cases (colposcope + mobile device)	Indication for colposcopy	User
Colposcopy clinic, PGIMER	28	Abnormal Pap smear=21 HPV positive=1 Asha Jyoti referral=6	Gynecologist
Screening in outreach setting (Asha Jyoti van)	202	Screening	Nurse

of colposcopy in the 230 women. Of the 21 women who underwent colposcopy for an abnormal Pap smear, the report of pap smear was high-grade squamous intra-epithelial lesion (HSIL) in four, atypical squamous cells, high grade (ASC-H) in two, low-grade squamous intraepithelial lesion (LSIL)/atypical squamous cells of undetermined significance (ASCUS)/atypical glandular cells of undetermined significance (AGUS) in 12, and persistent inflammatory in three.

Table 2 summarizes the four parameters assessed to compare image quality of the colposcope and the

**Table 2:** Image quality assessment parameters compared between colposcope and ColpPhon™

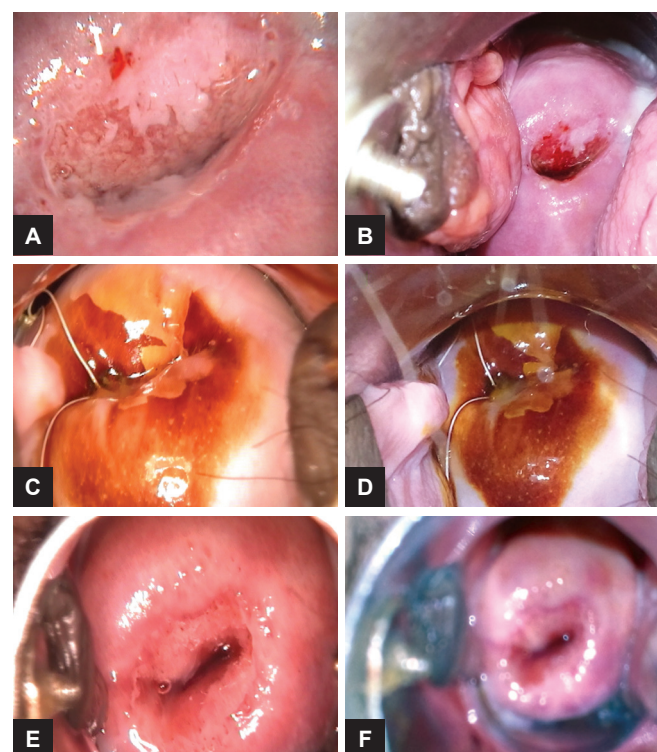
Feature	Colposcope					ColpPhon™
	5	4	3	2	1	
Brightness	5	19	1	0	0	0
	4	182	3	2	0	0
	3	13	5	1	0	0
	2	2	2	0	0	0
	1	0	0	0	0	0
Sharpness	5	19	2	0	0	0
	4	171	3	2	0	0
	3	19	5	1	0	0
	2	4	3	0	0	0
	1	1	0	0	0	0
Glare	5	17	1	0	0	0
	4	70	4	1	0	0
	3	119	4	2	0	0
	2	8	2	1	0	0
	1	1	0	0	0	0
Clarity	5	102	3	0	0	0
	4	82	2	1	0	0
	3	24	2	3	0	0
	2	6	2	1	0	0
	1	2	0	0	0	0

The image quality parameters of brightness, sharpness, glare and clarity were accorded a scale of 1 to 5 with 1: Very poor; 2: poor; 3: average; 4: good, and 5: excellent

ColpPhon™. For most cases, brightness and sharpness for images captured using ColpPhon™ had one grade lower rating than colposcope images. It was observed that glare was more in images captured with the ColpPhon™ and most cases had two grade lower rating than colposcope images. Although these image quality parameters for ColpPhon™ were slightly inferior to the colposcope, the overall image clarity was either good or excellent in 82% (184/225). Figures 1A to F show the image comparison.

Table 3 summarizes the assessment outcome comparison between Colposcope and ColpPhon™ images. The assessment was technically adequate in 76% (176/230) by the ColpPhon™ and in 86% (198/230) by the colposcope. The reasons for inadequate assessment by the ColpPhon™ in the 22 cases that could be assessed adequately by the colposcope were glare (excessive brightness resulting in blurring) in 15 followed by position of the cervix in four and nonvisualization of an acetowhite area in three.

Table 4 summarizes detailed results in the colposcopy clinic (n=28). Among these 28 cases, two could not be assessed technically by the colposcope due to a type 3 transformation zone. Among the 26 cases assessed adequately by the colposcope, 12 with acetowhite area, 4



**Figs 1A to F:** Comparison of colposcopic and ColpPhon™ images in three cases. ACW: Acetowhite. ColpPhon™ Image similar to Colposcope: (A) (case 14) Colposcope (ACW); (B) ColpPhon™ (ACW) PAP=HSIL, HPE=CIN 3; (C) (V 83) Colposcope (iodine negative); (D) ColpPhon™ (iodine negative) (PAP normal, biopsy; cervicitis) Colposcope image better than ColpPhon™; (E) (V 82) Colposcope; and (F) ACW not seen in ColpPhon™ (PAP normal)

**Table 3:** Assessment outcome comparison between colposcope and ColpPhon™

Colposcope	Adequate assessment		Inadequate assessment			
	Colposcopy clinic	Asha Jyoti van	Colposcopy clinic	Reason	Asha Jyoti van	Reason
	26/28	172/202	2/28	Type 3 TZ in 2	30/202	Type 3 TZ in 16, Blurred or glare in 5, Mucus in 4, Cervix Position in 2 Polyp in 3
ColpPhon™	23/28	153/202	5/28	Type 3 TZ in 2 Blurring/glare in 3	49/202	Type 3 TZ in 16, Blurring/glare in 17, Mucus in 4, Cervix Position in 6, Polyp in 3 ACW not seen in 3

**Table 4:** Details of important findings in colposcope and ColpPhon™ in colposcopy clinic (n=28)

	Colposcope	ColpPhon™	PAP	HPE
Image normal	8/26	5/23 (3 which could not be reported by phone were normal on colposcopy)	Normal=4 ASCUS=2 Inflammatory=1 AGUS=1	Benign polyp=2 Endometrial biopsy normal=1
Acetowhite areas	12/26	12/23	HSIL=2 ASC-H=1 LSIL=1 ASCUS=4 Inflammatory=2 Normal=2	CIN 2/3=3 CIN 1=1 Chronic cervicitis with squamous metaplasia=5 Normal=3
Acetowhite areas and iodine negative	4/26	4/23	HSIL=1 ASCUS=3	CIN 3=1 Chronic cervicitis with squamous metaplasia=2 Normal=1
Iodine negative	2/26	2/23	HSIL=1 ASC-H=1	CIN 3=1 Chronic cervicitis with squamous metaplasia=1

**Table 5:** Details of important findings in colposcope and ColpPhon™ in Asha Jyoti van (n=202)

	Colposcope	ColpPhon™	PAP	Histopathology
Image normal	141/172	124/153		
Acetowhite areas	17/172	15/153	Inflammatory=1 Normal=15 (one patient did not report for follow-up)	Chronic cervicitis with squamous metaplasia=6 Benign polyp=1
Acetowhite areas and iodine negative	7/172	7/153 (missed ACW but not iodine negative)	Normal=6 inflammatory 1	Chronic cervicitis with squamous metaplasia=4
Iodine negative	7/172	7/153	Normal=7	Chronic cervicitis with squamous metaplasia=1

with acetowhite and iodine-negative areas, and 2 with iodine-negative areas were identified by the colposcope and the ColpPhon™ both. The remaining eight cases had normal findings by the colposcope of which five were also normal by the ColpPhon™ and three could not be assessed by the ColpPhon™ due to blurred images or glare. The histopathological diagnosis of CIN 1 in one and CIN 2-3 was reported in five cases; all six had been identified as abnormal by the colposcope and ColpPhon™ both.

Table 5 summarizes detailed results in the Asha Jyoti van (n=202). Among these 202 cases, 30 could not be assessed technically by the colposcope as well as the ColpPhon™ due to reasons listed in Table 3. Of the 172 cases assessed adequately by the colposcope, 153 could also be assessed adequately by the ColpPhon™. Reasons for inadequate assessment by the ColpPhon™ in 19 cases are listed in Table 3. Women with abnormal finding by the colposcope were 31 (17 with acetowhite area, 7 with acetowhite and iodine-negative areas and 7 with iodine-negative areas) of whom 29 were

identified by the ColpPhon™ as well. The ColpPhon™ missed acetowhite areas in three women, though one of these three was identified as abnormal due to an iodine-negative area. However, in these 31 women with abnormal colposcopy findings, the PAP smear was either normal or inflammatory in 30 of 31. The histopathology in 12 of these women who underwent a cervical biopsy was benign (chronic cervicitis, squamous metaplasia, polyp).

The final diagnosis made on images acquired from each device had an agreement in 90% (208/230) women. Among the colposcopy clinic, the final diagnosis made on images acquired from each device had an agreement in 89% (25/28) women. Among the Asha Jyoti van cases, the final diagnosis made on images acquired from each device had an agreement in 90.5% (183/202) women. Importantly, an abnormality confirmed as CIN by histopathology in six women had been identified by the colposcope and the ColpPhon™ both. The three women in whom an acetowhite area, which was reported on colposcopy but missed by the ColpPhon™, had normal

Pap smears. Biopsy was done in only one of these and reported as chronic cervicitis.

## DISCUSSION

In the present study, we assessed the feasibility of digital technology by using a smartphone camera (ColpPhon™) to capture images of the cervix after application of acetic acid and Lugol's Iodine. These images were reviewed subsequently by two colposcopists and compared with images obtained in the same sitting with a digital video colposcope in a colposcopy clinic (n = 28) and in an out-reach setting by trained nurses (n = 202). This process is equivalent to recording digital images of the cervix while performing cervical cancer screening by VIA or VILI.

We observed that the overall clarity of the image obtained by the ColpPhon™ was "good" or "excellent" in 82% of the cases in whom the colposcopic images were "good" or "excellent" (184/225). The final diagnosis made on images acquired from each device had an agreement in 90% (208/230) cases, as the ColpPhon™ images rated as "average" (score = 3) in 24 cases were also appropriate for interpretation. This was similar among the colposcopy clinic (agreement in 89%; 25/28) cases and the Asha Jyoti van (agreement in 90.5%; 183/202) cases, which suggests that this technology is likely to work well in the hands of health care workers performing a VIA screening in out-reach areas.

An important observation was that an abnormality that was confirmed as CIN by histopathology in six women had been identified by the colposcope and the ColpPhon™ both. In three women, acetowhite area was reported on colposcopy but not by the ColpPhon™. The Pap smear was normal in all three and biopsy in one of them showed chronic cervicitis. The other two women were not biopsied, as the colposcopists interpreted it as a metaplastic change. Thus, a clinically relevant abnormality was identified by the colposcope and ColpPhon™ both.

One limitation of the ColpPhon™ was blurring due to glare (excessive brightness) in 15 women in whom the colposcope image was appropriate for interpretation. This can be improved by optimizing the camera, reducing the brightness, and incorporating features such as auto-adjustment for better image quality. The reflection of light by a metal speculum can also be taken into account while making these changes. Another limitation was that the position of the cervix precluded proper visualization in four women. This may be overcome to a certain extent by the skill of the health care personnel and expertise in manipulating the speculum to bring the cervix into view.

Capturing images of the cervix to review them subsequently for an abnormality has been reported earlier. Chen et al<sup>7</sup> reported digital cervicography in 119 cases with precancerous Pap smears in Taiwan. An 8-megapixel

Canon digital camera with a macro lens and a light source was used. The results of cervicography combined with the Reid colposcopic index were statistically significant ( $p < 0.05$ ), but more data were required to understand the discrepancies among Pap smear results, cervicography, and histopathology.

Parham et al<sup>8</sup> reported a cervical cancer prevention program using communication technology in Zambia. Nurses were trained to perform VIA aided by digital cervicography. Digital images were reviewed, and distance consultation sought if needed. Same-visit cryotherapy or referral for further evaluation by a gynecologist was offered. The Zambian system of "electronic cervical cancer control" delivered health care in low-resource environments and facilitated monitoring, evaluation, and continued education of primary health care workers and medical records documentation.

Catarino et al<sup>9</sup> evaluated the use of a smartphone for on- and off-site digital images after acid acetic application (D-VIA) diagnosis in Madagascar. The smartphone used was Samsung Galaxy S5, with a 16 megapixels camera. The flash mode (LED) was permanently activated. Women aged 30 to 65 years were recruited through a cervical cancer screening campaign. Each performed a human papillomavirus virus (HPV) self-sample as a primary screen. Women testing positive for HPV were referred for VIA followed by D-VIA, cervical biopsy, and endocervical curettage according to routine protocol. The D-VIA was emailed to a tertiary care center for immediate assessment. Ninety-five women underwent VIA triage; CIN was detected in 17.7 and 21.7% of digital images by on-site and off-site physicians, respectively. The on-site physician had a sensitivity of 66.7% (95% CI: 30.0–90.3) and a specificity of 85.7% (95% CI: 76.7–91.6); the off-site physician consensus sensitivity was 66.7% (95% CI: 30.0–90.3) with a specificity of 82.3% (95% CI: 72.4–89.1). A total of eight cervical neoplasia cases were detected by histopathology: two CIN1, two CIN2, two CIN3, and two invasive cancers. The on-site physician detected four of six CIN2+ lesions. A missed cancer by the on-site physician was detected by the D-VIA consensus among physicians in Geneva. Overall, two CIN2+ were missed and 18 healthy women were unnecessarily treated on-site. This pilot study supported the use of telemedicine for off-site diagnosis of CIN, with diagnostic performance similar to those achieved on-site. Further studies need to determine whether incorporation of smartphones to capture images of the cervix after acetic acid application in the cervical cancer screening program can improve screening efficiency in resource-poor countries.

The present study showed the feasibility of using low-cost technology for cervical cancer screening in the form of a mobile smartphone camera to capture images during a VIA screening. The use of this technology does

not require any sophisticated training. It can be used in areas having erratic access to electricity. The reviewing clinician is likely to be able to identify a clinically relevant abnormality from the captured images. Additional benefits would be in the form of medical records documentation and a quality check on the health care worker's capability and technique of performing VIA. Viewing the images captured by the health care workers would tell the reviewer whether their training and skill to perform a speculum examination and visualize the cervix in its entirety is appropriate. Feedback about the VIA-positive or negative cases reported by the health care workers would improve their skills.

## CONCLUSION

The present study demonstrates the feasibility of incorporating a mobile smartphone device to capture images of the cervix during visual inspection after acetic acid application. It offers portability, has low power requirements, and has negligible maintenance. In addition, the cost per test is low and it may help in medical records documentation and keep a quality check on the VIA screening being performed by health care workers. This simple technology may improve cervical cancer screening in resource-poor countries.

## REFERENCES

1. Ferlay J, Soerjomataram I, Ervik M, Dikshit R, Eser S, Mathers C, Rebelo M, Parkin DM, Forman D, Bray, F. GLOBOCAN 2012 v1.0, Cancer Incidence and Mortality Worldwide: IARC CancerBase No. 11 [Internet]. Lyon, France: International Agency for Research on Cancer; 2013. Available from: <http://globocan.iarc.fr>, accessed on 19/04/2016
2. Saxena U, Sauvaget C, Sankaranarayanan R. Evidence-based screening, early diagnosis and treatment strategy of cervical cancer for national policy in low- resource countries: example of India. *Asian Pac J Cancer Prev* 2012;13(4):1699-1703.
3. Nandakumar A, Ramnath T, Chaturvedi M. The magnitude of cancer cervix in India. *Ind J Med Res* 2009 Sep;130(3): 219-221.
4. Dailard C. HPV in the United States and developing nations: a problem of public health or politics. *The Guttmacher Report on Public Policy* 2003; 6: 4-15.
5. Arbyn M, Sankaranarayanan R, Muwonge R, Keita N, Dolo A, Mbalawa CG, Nouhou H, Sakande B, Wesley R, Somanathan T, et al. Pooled analysis of the accuracy of five cervical cancer screening tests assessed in eleven studies in Africa and India. *Int J Cancer* 2008 Jul 1;123(1):153-160.
6. Cremer M, Jamshidi RM, Muderspach L, Tsao-Wei D, Felix JC, Blumenthal PD. Digital camera assessment for detection of cervical intraepithelial neoplasia in rural El Salvador. *Int J Gynecol Obstet* 2005 Oct;91(1):42-46.
7. Chen ZP, Chen HM, Lee TT. Use of compact digital cervicography: an adjuvant screening tool for precancerous cervical lesions. *Taiwan J Obstet Gynecol* 2008 Jun;47(2):187-191.
8. Parham GP, Mwanahamuntu MH, Pfaendler KS, Sahasrabudde VV, Myung D, Mkumba G, Kapambwe S, Mwanza B, Chibwesa C, Hicks ML, et al. eC3--a modern telecommunications matrix for cervical cancer prevention in Zambia. *J Low Genit Tract Dis* 2010 Jul;14(3):167-173.
9. Catarino R, Vassilakos P, Scaringella S, Undurraga-Malinverno M, Meyer-Hamme U, Ricard-Gauthier D, Matute JC, Petignat P. Smartphone use for cervical cancer screening in low-resource countries: a pilot study conducted in Madagascar. *PLoS One* 2015 Jul;10(7):e0134309.